

## Wernicke Encephalopathy after Sleeve Gastrectomy. A Review of the Literature

Anastasios Angelou M.D<sup>1\*</sup>, Antonios Athanasiou M.D<sup>1</sup>, Theodoros Diamantis M.D Phd<sup>1</sup>, Christos Tsigkris M.D Phd<sup>1</sup>,  
Andreas Alexandrou M.D Phd<sup>1</sup>

1.Department of Surgery, Laiko Hospital, School of Medicine, University of Athens, Athens, Greece

### ABSTRACT

#### Objectives:

Bariatric surgery has been established as the cornerstone of treatment of morbid obesity with good immediate and long-term results. Nutrient deficiencies though, can be an important long-term complication and may lead to hematological, metabolic and especially neurological disorders which are not always reversible. Thiamine (vitamin B1) deficiency has been reported both after restrictive and malabsorptive procedures. The aim of this study is to review all cases that presented with Wernicke Encephalopathy after sleeve gastrectomy.

#### Methods:

A review of the literature was conducted to evaluate all sleeve gastrectomies performed till today and caused Wernicke encephalopathy to the patients. Demographic data, operative parameters, postoperative outcomes were collected and assessed.

#### Results:

A total of 13 studies, including 13 patients were analyzed. Patients ranged in age from 17 to 55 years. The onset of Wernicke encephalopathy occurred as early as 3 weeks after surgery to as late as 60 weeks after surgery. When symptoms of Wernicke encephalopathy developed, patients had lost from 19 kg up to 60 kg of body weight.

#### Conclusions:

Micronutrient deficiencies and particularly B1 deficiency can occur after LSG, although rarely. Preoperative nutritional assessment and postoperative follow-up plan, should signs of Wernicke's encephalopathy be traced, is recommended in all patients.

**Corresponding author:** A. Angelou M.D, Address: Laiko Hospital, Mikras Asias 75, Athens, Greece, Telephone : +30210291604, FAX : +30210291604

**Running title:** nutrition, pregnancy & bariatric surgery

**Keywords:** bariatric surgery; morbid obesity; nutrition; vitamin deficiency

**Received:** Sep 25,2017 **Accepted :** Oct 17,2017

**Published:** Nov 01,2017

## Introduction

Bariatric surgery is currently the most effective treatment modality to induce weight loss and ameliorate the various comorbidities of obesity [1,2]. However, bariatric interventions induce major changes in the anatomy and physiology of the gastrointestinal tract thus can be responsible for quite a range of side-effects, including nutritional deficiencies. Bariatric operations traditionally are divided to restrictive, malabsorptive or combined according to the mechanism they induce weight-loss. Malabsorptive procedures have been reported as having more sustainable long-term results in terms of weight loss and amelioration of related comorbidities compared to restrictive procedures, in exchange for more common post-operative nutritional deficiencies [3]. Restrictive procedures on the other hand are linked with a progressively attenuated weight-loss and metabolic result but have a more favorable long-term nutritional profile [4],[5],[6],[7]

Sleeve gastrectomy is currently the most commonly used bariatric procedure worldwide due to its very good immediate and quite promising long-term results [8] [9], [10] , [4]. Concerning its potential long-term nutritional disorders, it has been reported to have a safe profile, with Ferrum, calcium, and vitamin D deficiencies being the most commonly reported problems [7].

The aim of this study is to focus on the thiamine (vitamin B1) deficiency and the ensuing Wernicke encephalopathy which although a rare complication can have grave consequences.

## Materials And Methods

We searched MEDLINE, Ovid, Embase, ISI (Science Citation Index), and Google Scholar independently and in duplicate, using the MeSH terms [Wernicke encephalopathy and bariatric surgery or obesity surgery or sleeve gastrectomy]. We reviewed references of all reports for additional cases. We used the related articles link and searched the citations of reports in the ISI Science Citation Index to identify additional reports. We reviewed the full text and the abstracts of these articles and reviewed the data on age, sex, comorbidities, onset duration, weight loss, neurologic findings and outcomes. All of the included studies were case reports. In order to avoid missing data that could be pooled with other long-term

deficiencies, we also searched for published reviews of long-term results after sleeve gastrectomy with special interest on nutritional deficiencies.

## Inclusion and Exclusion criteria

Included were case reports, case series, or cohort studies describing Wernicke encephalopathy after sleeve gastrectomy. Cases included were those that met the operational case definition of Wernicke encephalopathy, comprising two of the following four symptoms: 1) dietary deficiencies, 2) oculomotor abnormalities, 3) cerebellar dysfunction, and 4) altered mental state or mild memory impairment. We independently reviewed the full text of these articles and abstracted data on age, sex, duration of onset, type of surgery, severity of weight loss, predisposing factors, radiographic findings, unique neurologic features, and outcomes.

## Results

We identified 13 Figure 1 case reports. Patient's demographics and clinical characteristics can be seen in Tables 1, 2. Briefly, most patients were men (n=7) in their twenties and thirties.[11-16] The onset of Wernicke encephalopathy occurred as early as 2 weeks post-operatively, to as late as 60 weeks after surgery. When symptoms of Wernicke encephalopathy developed, patients had lost from 19 kg up to 60 kg of body weight. The respective data of percentage of excessive weight-loss for each patient were not universally reported.

The triad of WE includes encephalopathy, oculomotor abnormalities and gait ataxia. This triad was reported in five of identified SG cases.[14-18] The most common sign was altered mental status.[14-16,18,19] However, WE can be underestimated because not all of the elements are present at the onset of the disease. The symptoms of subclinical thiamine deficiency include fatigue and lethargy as reported in most cases. Other atypical clinical signs and symptoms are peripheral neuropathy, vestibular dysfunction, dysphagia and depression.

In most of the reported cases, serum thiamine levels were reduced. But the serum and urinary tests in symptomatic patients are not sensitive and remain technically difficult and time-consuming. MRI is the diagnostic tool of choice, with a high sensitivity and specificity for WE.[20]

All patients were treated with parenteral thiamine

**Table 1: Obese patients' demographics**

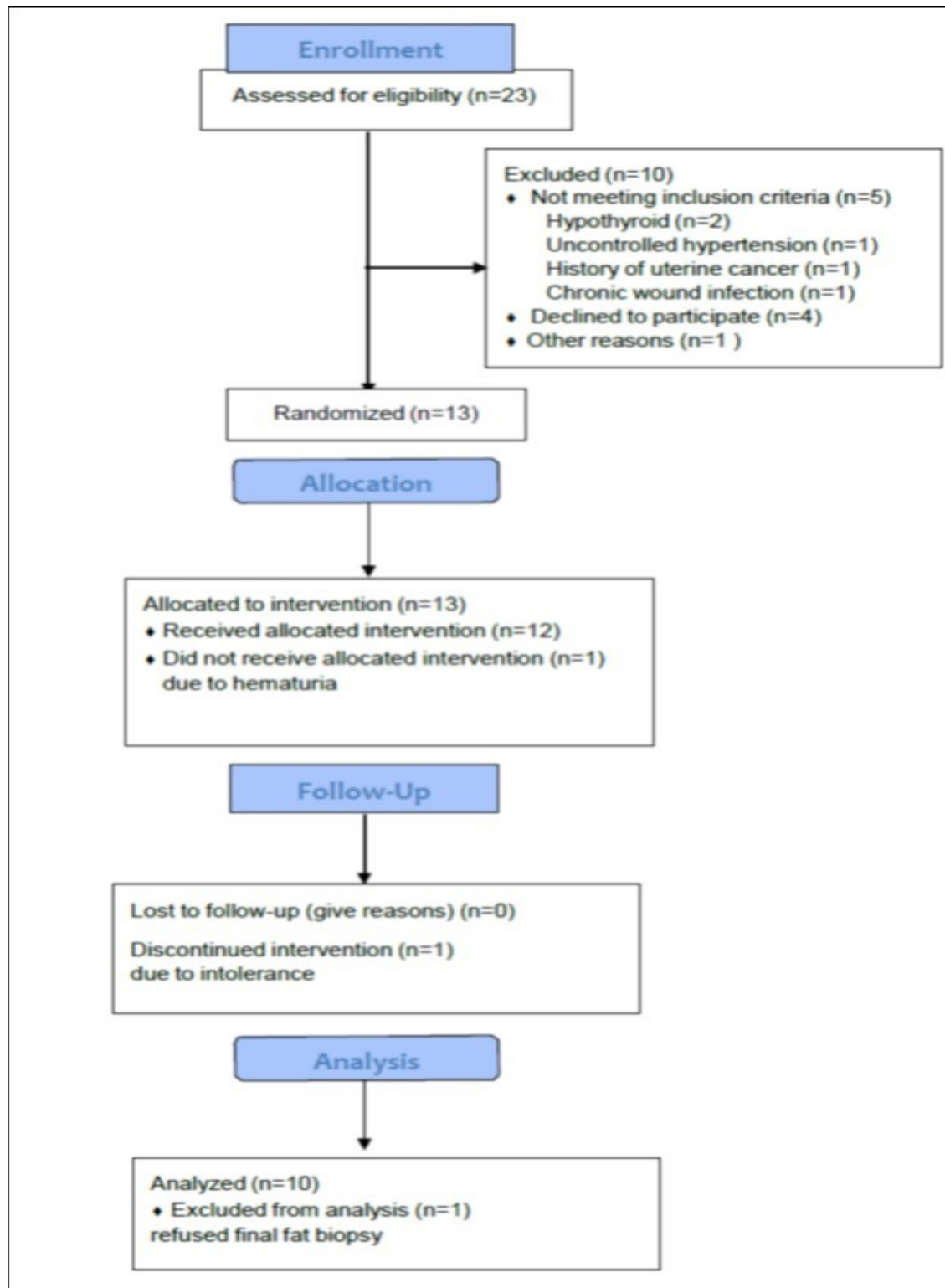
Author	Sex/ age	Onset (wk)	Neurologic deficits	Thiamine levels	BMI* (weight loss-kg)	Comorbidities
Cerruti et al. [11]	M 33	18	Paresthesia, dysarthria	-	47(60)	-
Jeong et al. [12]	M 24	60	dysarthria	15nmol/L (20- 50)	47,1( 60)	DM**, HTN±
Makarewicz et al. [17]	F 38	4	Paresis of left tibial nerve, loss of sensa-	-	62	DM, HTN
Moize et al. [33]	F 35	8	-	11ng(35-91)	49,8 (19,5)	DM, HTN
Scarano et al. [34]	F 27	12	Lower limb paresthesia	Urine 22mg (40- 90)	43,7	-
Sharabi et al. [35]	F	8	-	17 ng(28-85)	-	-
Saab et al. [36]	F 27	3	-	43(70-180)	-	-
Samanta [19]	F 17	3	Paresthesia, nystagmus	<2 nmol/L (8- 15)	51.6 kg/m <sup>2</sup>	-
Serlin et al.[18]	F 37	10	confusion, postural im- balance and visual impair- ment	13.9 ng/mL (32-95 ng/mL)	43 (25.8)	-
Dirani et al.[13]	M 20	3	visual impair- ment,nystagm	-	45	-
Landais et al.[14]	M 31	4	nystagmus, ataxia, confu- sion	55,9 nmol/L ( 66,5–200)	47	
Pardo-Aranda et al.[15]	M 20	5	confusion, motor ataxia, diplopy and	12.2 ng/mL (35–91 ng/mL)	50.17	-
Kröll et al.[16]	M 55	8	confusion, motor ataxia and nystagmus		67 kg/m <sup>2</sup>	arterial hyperten- sion, type 2 diabetes mellitus, dyslipidemia, NASH, GERD, obstructive sleep apnea

\*BMI: Body Mass Index \*\*DM: Diabetes Mellitus ± HT: Hypertension

**Table 2: Clinical characteristics of patients with Wernicke encephalopathy**

Author	Sleeve complication	Therapy B1	Glycemic status
Cerruti et al.[11]	-	1500mg/iv-500mg orally	-
Jeong et al. [12]	Staple- line leakage	Iv 100mg for 10d then orally	DM**
Makarewicz et al. [17]	Edema of gastric wall, functional stenosis of the stomach	Iv 50mg per day	-
Moize et al. [33]	Laceration of the mucosa of GEJ±±	100mgx3 +5mg folic orally	DM
Scarano et al. [34]	-	1800mcg im/w, iv 500 mg x3 then orally 100mg x1	Eyglucemic
Sharabi et al. [35]	Inguinal abscess-paralytic ileus	Iv 600 mg x1	-
Saab et al. [36]	-	Iv 100 mg-orally 100 x3	-
Samanta [19]	-	Iv 500 mg x3	Eyglucemic
Serlin et al.[18] Dirani et al.[13]	- Fistulawith thoraco-abdominal abscess	Iv 500 mg x3 IM 500mgx1 for 5 days	Eyglycemic
Landais et al.[14]	-	Iv 1g/d	Eyglycemic
Pardo-Aranda et al.[15]	-	IV 100MG/d and orally 600 mg per day	Eyglycemic
Kroll et al.[16]	-	i.v 300 mg three times daily	DM

\*\* DM: Diabetes mellitus ±± GEJ: Gastroesophageal junction



administration. Four patients had a complete recovery. Eight patients had residual neurologic defects, including Korsakoff psychosis, persistent amnesic state with antegrade amnesia and retrograde memory loss, memory problems, persistent ataxia, nystagmus, and neuropathy. One patient died from an unrelated cause (septic shock).

## DISCUSSION

Wernicke Encephalopathy (WE) was first described by Carl Wernicke in 1881 as "superior acute hemorrhagic poli-encephalitis". Despite the fact that WE was described so early, it took more than half a century to recognize the relation between the disease and the thiamine deficiency. Thiamine is a water-soluble vitamin of the B complex. It is involved with several other enzymes and co-enzymes in the Krebs cycle and the pentose phosphate pathway and plays a central role in cerebral metabolism. Thiamine deficiency in turn instigates brain injury by inhibiting metabolism in regions of the brain with high metabolic demand. The most frequently affected regions are the medial thalamus and periventricular region of the third ventricle, periaqueductal area, mammillary bodies and midbrain tectum (superior and inferior colliculi). Often, there is a selective loss of the Purkinje cells in the cerebellum. Although alcoholic patients account for more than 90% of both acute and chronic WE in developed countries, acute WE can also occur in cases of malnutrition (prolonged fasting, parenteral nutrition without the addition of thiamine) or even in cases of prolonged vomiting [21] [22]. Suddenly occurring in its most common form, WE is classically characterized by a clinical triad including reduced consciousness, a cerebellar syndrome (in particular ataxia and dysarthria) as well as oculomotor disorders (ophthaloplegia, nystagmus). The classic triad of WE was present in only 16% of patients in a retrospective autopsy review [23]. According to the Caine criteria [22], the diagnostic criteria for Wernicke encephalopathy require 2 of the following 4 features: (1) dietary deficiency, (2) oculomotor abnormality, (3) cerebellar dysfunction, and (4) confusion or mild memory impairment. These criteria have a very high inter-observer reliability for the diagnosis.

Bariatric surgery can imitate or be complicated by all the above mentioned conditions. The risk of WE

involvement is highly dependent on the type of bariatric surgery performed. Purely restrictive operations, such as laparoscopic adjustable gastric banding, sleeve gastrectomy and vertical banded gastroplasty, tend to cause fewer deficiencies than do malabsorptive procedures such as laparoscopic Roux-en-Y gastric bypass and biliopancreatic diversion. Thiamine deficiency is reported to occur more often after RYGB. The possible reason is that maximal absorption of thiamine takes place in the jejunum, which can be affected by anatomical changes after a RYGB. Clements et al. noted a significant incidence rate up to 18 % 2 years after a RYGB. [24-26], [27], [28], [29],[13]. Following SG for morbid obesity more particularly, several factors, including the restriction in energy intake, prolonged vomiting, rapid and excessive weight loss, and medication non-compliance, have been associated to the development of WE [30] [31]. In particular, vomiting represents a well-known complication of SG, which may be due to surgery-related complications such as the presence of an anatomical or functional gastric stricture, a leak or a staple-line bleeding.

Despite the availability of different diagnostic modalities, including laboratory evaluation, electroencephalography, and brain imaging, WE remains a clinical diagnosis, requiring a high index of suspicion. The presumptive diagnosis may be confirmed by the measurement of thiamine and its phosphate esters in the human blood by high-performance liquid chromatography (HPLC) or by measuring the activity of the enzyme transketolase in the erythrocytes [32]. However, because of the technical difficulty and lack of specificity of these tests, which additionally require several days to perform, their aid in the process of decision-making is limited. Neuroimaging studies are powerful tools in supporting the diagnosis of WE. Brain MRI offers the best means to establish a definitive diagnosis of WE, having a low sensitivity of 53%, but a high (93%) specificity rate [20]. Common brain MRI findings are hyper-intense signals in the dorsal medial thalamic nuclei, the peri-aqueductal gray area, and the third and fourth ventricle [31]. In the acute setting a mammillary body enhancement may be revealed, whereas in a more chronic stage a mammillary body atrophy may be shown [20].

The mainstay of treatment of WE is the administration of thiamine. The standard recommenda-

tion is 200 mg, 3 times per day. The intravenous route is preferred instead of the intramuscular one, while the oral route in the acute setting is not recommended due to decreased gastrointestinal absorption or even not applicable due to circumstances precluding normal oral diet. However, several authors state that the dose should be increased to 500 mg thiamine 3 times per day [22]. With these thiamine administration schemes, WE has been reported to be treated with very good results, since it seems that the majority of patients can be totally cured while in a minority some minor residual neurological defects may ensue.

This study has of course some limitations. It is retrospective, the number of the reported cases is low, and it can always happen that despite the exhaustive search some cases may be missed. Despite these, this study tries to address the problem of a rare cause of severe morbidity after a rather commonly used operation like SG and as such, it can be helpful for the clinician, who although rarely, may encounter such a patient.

## CONCLUSIONS

In summary, this study reaffirms that only a small number of patients have been reported as having suffered from clinically significant B1 deficiency after SG for morbid obesity. Physicians should be highly suspicious for the diagnosis of Wernicke's encephalopathy in cases of rapidly altered mental status occurring in patients with malnutrition or malabsorption as a consequence of prolonged vomiting after SG. Since B1 levels are not included either in the pre-operative nutritional assessment or in any rigorous postoperative follow-up plan, the parenteral administration of high doses of B1 in all suspicious cases is imperative and usually results in the resolution of the symptoms.

## References:

1. Sjostrom L, Narbro K, Sjostrom CD, Karason K, Larsson B, Wedel H, Lystig T, Sullivan M, Bouchard C, Carlsson B, Bengtsson C, Dahlgren S, Gummesson A, Jacobson P, Karlsson J, Lindroos AK, Lonroth H, Naslund I, Olbers T, Stenlof K, Torgerson J, Agren G, Carlsson LM, Swedish Obese Subjects S: Effects of bariatric surgery on mortality in Swedish obese subjects. *N Engl J Med* 2007;357:741-752.
2. Courcoulas AP, Christian NJ, Belle SH, Berk PD, Flum DR, Garcia L, Horlick M, Kalarchian MA, King WC, Mitchell JE, Patterson EJ, Pender JR, Pomp A, Pories WJ, Thirlby RC, Yanovski SZ, Wolfe BM, Longitudinal Assessment of Bariatric Surgery C: Weight change and health outcomes at 3 years after bariatric surgery among individuals with severe obesity. *JAMA* 2013;310:2416-2425.
3. Mechanick JI, Youdim A, Jones DB, Garvey WT, Hurley DL, McMahon MM, Heinberg LJ, Kushner R, Adams TD, Shikora S, Dixon JB, Brethauer S, American Association of Clinical E, Obesity S, American Society for M, Bariatric S: Clinical practice guidelines for the perioperative nutritional, metabolic, and nonsurgical support of the bariatric surgery patient--2013 update: cosponsored by American Association of Clinical Endocrinologists, The Obesity Society, and American Society for Metabolic & Bariatric Surgery. *Obesity (Silver Spring)* 2013;21 Suppl 1:S1-27.
4. Diamantis T, Apostolou KG, Alexandrou A, Griniatsos J, Felekouras E, Tsigris C: Review of long-term weight loss results after laparoscopic sleeve gastrectomy. *Surg Obes Relat Dis* 2014;10:177-183.
5. Alexandrou A, Athanasiou A, Michalinos A, Felekouras E, Tsigris C, Diamantis T: Laparoscopic sleeve gastrectomy for morbid obesity: 5-year results. *Am J Surg* 2015;209:230-234.
6. Himpens J, Dobbeleir J, Peeters G: Long-term results of laparoscopic sleeve gastrectomy for obesity. *Ann Surg* 2010;252:319-324.
7. Malinowski SS: Nutritional and metabolic complications of bariatric surgery. *Am J Med Sci* 2006;331:219-225.
8. Angrisani L, Santonicola A, Iovino P, Formisano G, Buchwald H, Scopinaro N: Bariatric Surgery Worldwide 2013. *Obes Surg* 2015;25:1822-1832.
9. Gabaudan C, La-Folie T, Sagui E, Soulier B, Dion AM, Richez P, Brosset C: [Wernicke encephalopathy after subtotal gastrectomy for morbid obesity]. *Rev Neurol (Paris)* 2008;164:463-467.
10. Rosenthal RJ, International Sleeve Gastrectomy Expert P, Diaz AA, Arvidsson D, Baker RS, Basso N, Bellanger D, Boza C, El Mourad H, France M, Gagner M, Galvao-Neto M, Higa KD, Himpens J, Hutchinson CM, Jacobs M, Jorgensen JO, Jossart G, Lakdawala M, Nguyen NT, Nocca D, Prager G, Pomp A, Ramos AC, Rosenthal RJ, Shah S, Vix M, Wittgrove A,

- Zundel N: International Sleeve Gastrectomy Expert Panel Consensus Statement: best practice guidelines based on experience of >12,000 cases. *Surg Obes Relat Dis* 2012;8:8-19.
11. Cerutti D, Guilpain P, Schiffmann A, Riviere S, Carra C, Labauge P, Le Quellec A: [Serious clinical manifestations of vitamin deficiency after a "sleeve" gastrectomy: role of psychogenic anorexia]. *Rev Med Interne* 2014;35:609-612.
  12. Jeong HJ, Park JW, Kim YJ, Lee YG, Jang YW, Seo JW: Wernicke's Encephalopathy after Sleeve Gastrectomy for Morbid Obesity - A Case Report. *Ann Rehabil Med* 2011;35:583-586.
  13. Dirani M, Chahine E, Dirani M, Kassir R, Chouillard E: More than a Case Report? Should Wernicke Encephalopathy After Sleeve Gastrectomy be a Concern? *Obes Surg* 2017
  14. Landais A, Saint-Georges G: [Wernicke's encephalopathy following sleeve gastrectomy for morbid obesity]. *Rev Med Interne* 2014;35:760-763.
  15. Pardo-Aranda F, Perez-Romero N, Osorio J, Rodriguez-Santiago J, Munoz E, Puertolas N, Veloso E: Wernicke's encephalopathy after sleeve gastrectomy: Literature review. *Int J Surg Case Rep* 2016;20:92-95.
  16. Kroll D, Laimer M, Borbely YM, Laederach K, Candinas D, Nett PC: Wernicke Encephalopathy: a Future Problem Even After Sleeve Gastrectomy? A Systematic Literature Review. *Obes Surg* 2016;26:205-212.
  17. Makarewicz W, Kaska L, Kobiela J, Stefaniak T, Krajewski J, Stankiewicz M, Wujtewicz MA, Lachinski AJ, Sledzinski Z: Wernicke's syndrome after sleeve gastrectomy. *Obes Surg* 2007;17:704-706.
  18. Serlin T, Moisseiev E: Fundus Findings in Wernicke Encephalopathy. *Case Rep Ophthalmol* 2017;8:406-409.
  19. Samanta D: Dry beriberi preceded Wernicke's encephalopathy: Thiamine deficiency after laparoscopic sleeve gastrectomy. *J Pediatr Neurosci* 2015;10:297-299.
  20. Antunez E, Estruch R, Cardenal C, Nicolas JM, Fernandez-Sola J, Urbano-Marquez A: Usefulness of CT and MR imaging in the diagnosis of acute Wernicke's encephalopathy. *AJR Am J Roentgenol* 1998;171:1131-1137.
  21. Skeen MB: Neurologic manifestations of gastrointestinal disease. *Neurol Clin* 2002;20:195-225, vii.
  22. Chaves LC, Faintuch J, Kahwage S, Alencar Fde A: A cluster of polyneuropathy and Wernicke-Korsakoff syndrome in a bariatric unit. *Obes Surg* 2002;12:328-334.
  23. Harper CG, Giles M, Finlay-Jones R: Clinical signs in the Wernicke-Korsakoff complex: a retrospective analysis of 131 cases diagnosed at necropsy. *J Neurol Neurosurg Psychiatry* 1986;49:341-345.
  24. Giusti V, Suter M, Heraief E, Gaillard RC, Burckhardt P: Effects of laparoscopic gastric banding on body composition, metabolic profile and nutritional status of obese women: 12-months follow-up. *Obes Surg* 2004;14:239-245.
  25. Clements RH, Katasani VG, Palepu R, Leeth RR, Leath TD, Roy BP, Vickers SM: Incidence of vitamin deficiency after laparoscopic Roux-en-Y gastric bypass in a university hospital setting. *Am Surg* 2006;72:1196-1202; discussion 1203-1194.
  26. Baptista V, Wassef W: Bariatric procedures: an update on techniques, outcomes and complications. *Curr Opin Gastroenterol* 2013;29:684-693.
  27. Saltzman E, Karl JP: Nutrient deficiencies after gastric bypass surgery. *Annu Rev Nutr* 2013;33:183-203.
  28. Hammer HF: Medical complications of bariatric surgery: focus on malabsorption and dumping syndrome. *Dig Dis* 2012;30:182-186.
  29. Levinson R, Silverman JB, Catella JG, Rybak I, Jolin H, Isom K: Pharmacotherapy prevention and management of nutritional deficiencies post Roux-en-Y gastric bypass. *Obes Surg* 2013;23:992-1000.
  30. Aasheim ET: Wernicke encephalopathy after bariatric surgery: a systematic review. *Ann Surg* 2008;248:714-720.
  31. Watson WD, Verma A, Lenart MJ, Quast TM, Gauerke SJ, McKenna GJ: MRI in acute Wernicke's encephalopathy. *Neurology* 2003;61:527.
  32. Talwar D, Davidson H, Cooney J, St JRD: Vitamin B (1) status assessed by direct measurement of thiamin pyrophosphate in erythrocytes or whole blood by HPLC: comparison with erythrocyte transketolase activation assay. *Clin Chem* 2000;46:704-710.
  33. Moize V, Ibarzabal A, Sanchez Dalmau B, Flores L, Andreu A, Lacy A, Vidal J: Nystagmus: an uncommon neurological manifestation of thiamine deficiency as a serious complication of sleeve gastrectomy. *Nutr Clin Pract* 2012;27:788-792.



34. Scarano V, Milone M, Di Minno MN, Panariello G, Bertogliatti S, Terracciano M, Orlando V, Florio C, Leongito M, Lupoli R, Milone F, Musella M: Late micronutrient deficiency and neurological dysfunction after laparoscopic sleeve gastrectomy: a case report. *Eur J Clin Nutr* 2012;66:645-647.
35. Sharabi S, Bisharat N: Wernicke encephalopathy after sleeve gastrectomy. *Isr Med Assoc J* 2012;14:708-709.
36. Saab R, El Khoury M, Farhat S: Wernicke's encephalopathy three weeks after sleeve gastrectomy. *Surg Obes Relat Dis* 2014;10:992-994.